

## Research Article

### DR JOHN HOLT'S UHF RESONANCE – SIRT<sub>2</sub>, PHENOTYPES, ACTIN & NUCLEI: AN HYPOTHESIS (NUMBER 2)

\* Malcolm Traill

Clinical Pathologist (Retired), Castlemaine, Victoria, Australia.

Received 14<sup>th</sup> January 2023; Accepted 15<sup>th</sup> February 2023; Published online 30<sup>th</sup> March 2023

#### ABSTRACT

The proposal here is that the radiowave energy used by Dr John Holt (Radiotherapist, Western Australia) to treat cancer, caused NAD<sup>+</sup> to be generated. This fuelled the deacetylase SIRT<sub>2</sub>, which degraded cortical actin, depriving the plasma membrane of its support base needed by E-cadherin for cell-to-cell adhesion and the maintenance of cell morphology: the post-treated appearance then resembling an epithelial-like cell phenotype, yet with gaps between the cells and poor epithelial-like cell-to-cell relationships. This hypothesis suggests that the cell changes follow the action of SIRTUIN2 activity stimulated by the NAD<sup>+</sup> and not the factors typically involved with EMT/MET. **Conclusion:** Holt's UHF treatments had effects on cancer cytology not well appreciated previously.

**Keywords:** Cancer, UHF, Microwave, Resonance, NAD<sup>+</sup>, SIRT<sub>2</sub>, Actin, E-cadherin, PARP1, Parthanatos, MET

#### INTRODUCTION

Dr John Holt, Radiotherapist of Perth, Western Australia, brought a Tronado machine into Australia. Initially, it could deliver ~2,000 Watt of ultra high frequency [UHF] radio waves at ~434 MHz via a cylindrical array of folded dipoles around a seated patient. Whilst purchasing it, Holt observed that the current drawn by the machine when a patient with cancer was in it was ~225 W, but when Holt was in it, the current dropped to ~195 W. Later, with the use of a frequency analyzer, he described emissions at, above and below the machine's frequency of 434 MHz. Holt believed that the UHF 434 MHz had a specific effect upon cancers; it was not a typical form of

Hyperthermia (although patients were warmed). His belief was supported by a) the power change when a patient with cancer entered the UHF field, b) by the "resonance" effect using a frequency analyser, and c) changes seen in histopathological examinations of irradiated tumours. An hypothesis to explain the described "resonance" has been published (Traill 2022). A year or so after starting to use the Tronado machine for UHF treatments, Holt sought (by what was possible then), evidence that there was some cellular effect, that the UHF effect was specific and not simply due to heat (Holt, 1979). He published photomicrographs of the before and after histopathology for a few cancers that had been irradiated by VHF(=UHF) with minimal prior applications of other treatments:

Table 1

(Figures are black/white in the publication)

Holt's Figure	Anatomical site	Primary site	Hours post UHF	Holt's cytology	Current Author's Opinion
1	Iliac crest (bone)	Prostate	72 hours	"Faintly-stained globules". . "Presumably coagulation . . normal RBC & white blood cells"	Non-specific coagulative necrosis +/- infarction: +/- heat effect ?
2	"	"	+ 48 hours (= Total 120 hours)	"Normal acute inflammatory reaction."	"Difficult." Holt probably correct, neutrophils and lymphocytes. Cancer cells gone
3	"	"	+ 96 hours (=Total 216 hours)	"Acute inflammatory reaction." "UHF did not harm to normal cells"	"Difficult." More monocytes/macrophages and lymphocytes.
17	Upper femur (bone)	Adeno- carcinoma Breast	Completed UHF course 96 hours before	"Cancer cells are dead or dying. Few inflammatory cells."	Similar to (Holt's) Figure 1. Possibly pools of blood
19	Not stated - Breast assumed	Adeno- carcinoma Breast	Baseline (0 hour) (UHF intensity less than 20 mm W/cm <sup>2</sup> *)		See photomicrograph & analysis below
20	"	"	At completion of a course of UHF	"Mitotic figures ↑. . . now anaplasia. Growth rate ↑ x3-4."	See photomicrograph & analysis below

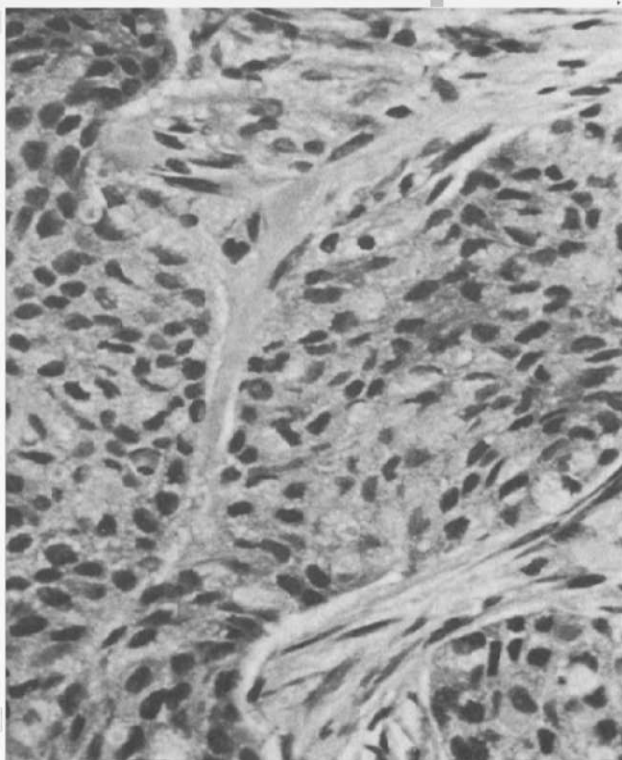
(\*Not considered high power)

\*Corresponding Author: Malcolm Traill

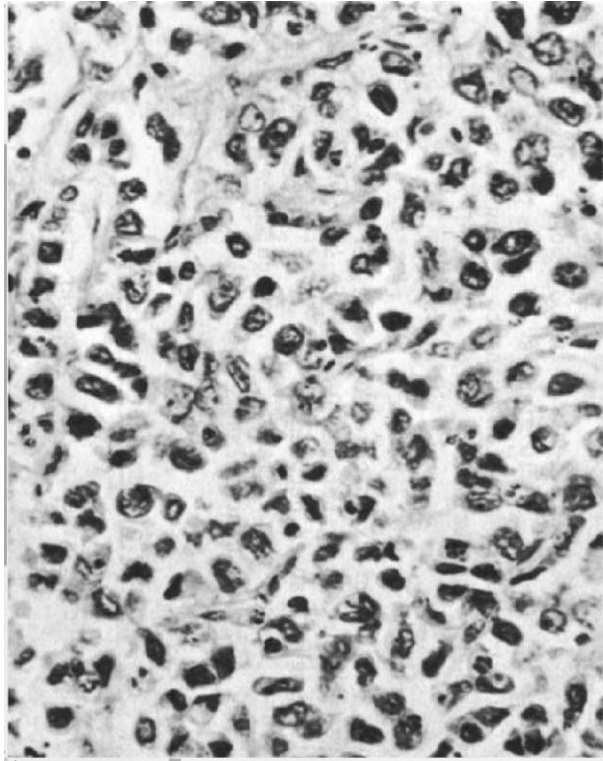
Clinical Pathologist (Retired), Castlemaine, Victoria, Australia. Email: [matraill@primus.com.au](mailto:matraill@primus.com.au)

Of the examples presented by Holt, 2 patients had cancer infiltration in cancellous bone. If tumour develops swelling (e.g. because of the heat) within the enclosed space, the limited expansion may bring about “end artery” vascular occlusion, causing infarction +/- simple heat effects. These effects would be non-specific, and do not indicate any specific UHF effect. However, the patterns presented seem to indicate that the UHF treatment did have some effects on cancers when in cancellous bone. But, being non-specific, they are not considered further here. Only one patient had 2 biopsies (baseline and after UHF, taken “close to the original site”). (The details are sparse). These examples (**Figures 1a & 1b** below) provide Histopathology examples that may reveal some of the “non-heat” effects of UHF 434 MHz on cancer. The Author attended a female patient with advanced leiomyosarcoma of the uterus. Her baseline histopathology section is **Figure 2a**. She had a full course of the UHF treatment, using Holt’s protocol (with the “GBA” of oxidized glutathione) and one hyperthermia treatment with 5-Fluorouracil. She attended a hospital some 41 days later, when the second histopathology section was obtained. A photomicrograph of this is **Figure 2b**. Both post UHF treatments (**Figure 1b & 2b**) show remarkable changes.

**Patient 1 (Figures 1a & 1b). The photomicrographs were copied from a publication by Holt (1979):**



**Figure 1a** Magnifications not provided – probable microscope gains ~x100

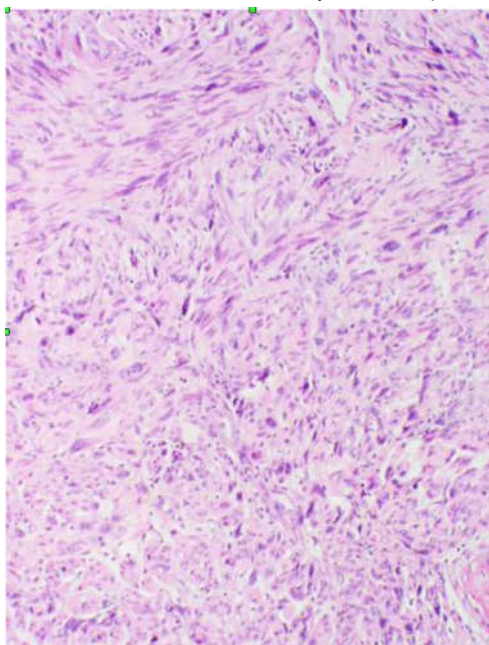


**Figure 1b**

Copy quality is not good.

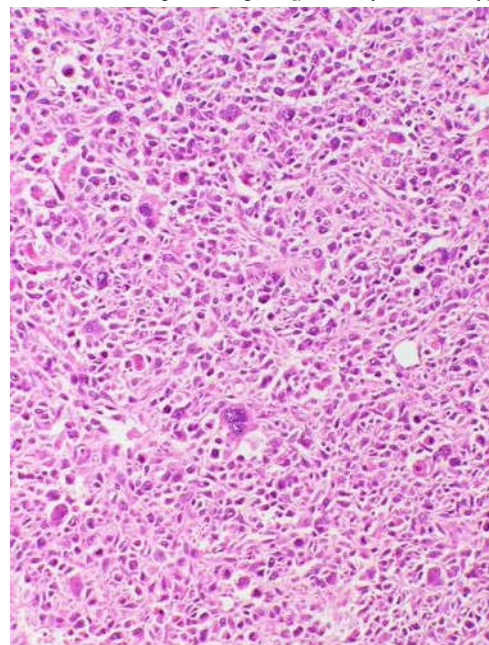
The patient had an adenocarcinoma of the breast. In **Figure 1a** (Pre-treatment) there is slight “streaming” of the oval nuclei (mid-right), being a mild mesenchymal-like phenotype. Biopsy for **Figure 1b** was said to be near the same site as that for Figure 1a. She had been treated with “a course of VHF (=UHF) 434 MHz at an intensity of below 20 mm w/sq cm” (medium/“sub-lethal” intensity, no intravenous oxidizing agent). There is clearly an appreciable difference in cellular patterns, being now “anaplastic and epithelial-like” (histology specimen quality “fair.”). Noticeable are nuclear changes – with generally very irregular outlines, showing small and large dense forms (left, lower third and bottom.) Spaces between cells may be slightly increased. Cytoplasmic detail is difficult to assess – there seem to be reticular wisps and spaces between with little typical cell-to-cell contact + possibly oedema. (It resembles a sub-confluent monolayer in cell culture.)

(Dr Holt reiterated these basic observations, but may have interpreted the nuclear changes in Fig 1b [probably incorrectly] as mitotic figures.)



**Figure 2a**

Magnification not provided – probable microscope gain ~x100



**Figure 2b**

Magnification not provided – probable microscope gain ~x100

**Figure 2a:** This patient (presenting 22/3/2002) had a leiomyosarcoma of the uterus – a mesenchymal tumour. Pre-treatment histopathology: Note the streaming and weaving bundles of oval nuclei and cells, with few gaps between the cells. There are numerous giant nuclei (typical).

**Figure 2b:** The patient had a course (x15) of UHF 434 MHz+oxidizing infusion) then a single Fever-Range Hyperthermia session with chemotherapy. The recurrence (above) was biopsied ~41 days subsequently. The Fever-Range Hyperthermia + chemotherapy would be unlikely, after the time gap, to have contributed much to the appearances above. The cells have lost the spindle/streaming appearance, the cell-to-cell contact, and adhesion, with the appearance of large, multi-nucleated giant cells and what appears to be nuclear fragmentation. The general eosinophilia, mainly cytoplasmic (from miRNA ? & might be relevant.) (An amazing change !)

**Table 2.** A number of important features are shared by both examples: **Figure 1b** and **Figure 2b:**

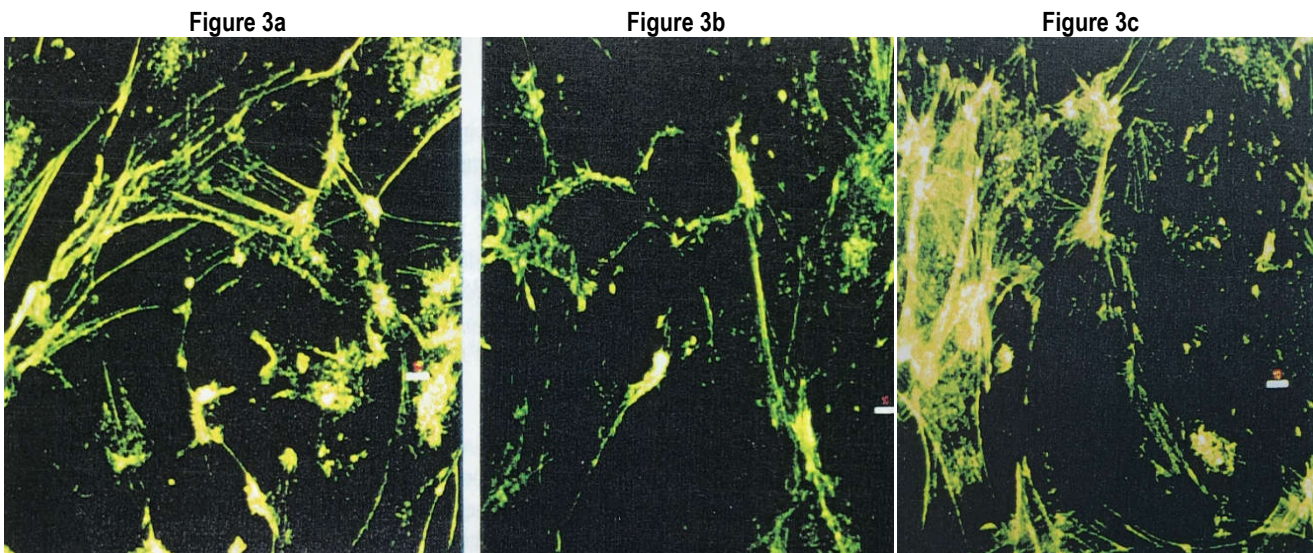
These are:

Phenotype feature	Figures 1a & 2a (baseline)	Figures 1b & 2b (Post-UHF +/- GBA)
Nuclear pattern	Streaming/oval	Fragmented small/large bizarre forms
Nuclear integrity	Smooth outlines, generally similar sizes	Fragmented small/large bizarre forms
Cell outline	Smooth	Stellate/polyhedral
Giant Cells	Few (if any)	Numerous and some very large
Cell-to-cell contact	Intact	Considerable loss ~universal loss
Inter-cellular spaces	Nil identified	Considerable/universal spaces

The noticeable features of the two examples show similarities and, whilst the sample size is small and there are aspects which may create doubts, attention will now be given to trying to elucidate the mechanism by which the UHF 434 MHz (+/- oxidizing agent) may have given rise to anomalous transformations. There are some features **inconsistent** with “typical” phenotypical transformations, as from mesenchymal to epithelial (MET) (Thiery *et al.*, 2009) – Whilst the morphology (cellular outlines) would seem to have changed from mesenchymal (spindle) to epithelial-like (~rounded), there are clear, acquired spaces between the cells, implying a loss (or ineffectiveness) of E-cadherin molecules (showing a lack of cohesion). Adhesion lack is an important feature of the mesenchymal phenotype and contributes to motility. So, there is a notable disparity, not easily reconciled with the current studies of EMT/MET.

**SUPPORT**

Another indication of factors that may be involved comes from a study of cellular actin filaments exposed to UHF 434 MHz : Holt claimed (Holt 2000) that he “. . . commissioned and financed a research program . . . (and) chose Dr Peter French.” French (and others) later published *in vitro* cell culture studies for the use of cellular telephones at 825-845 MHz, (Donnellan *et al.*, 1997). (Apart from Holt’s presentation of the “personal communication” of French’s work at 434 MHz, it may not have been published elsewhere. Technique details are sparse. The photomicrographs of cytoplasmic organelles do have scale indicators, possibly 1 µm).



**Figures: 3a.** “Non-treated A172b (human glioma cells). Before irradiation with 434 MHz.” **3b.** “434 MHz 10 minute exposure to 2 Watts output (a power density producing an average SAR of 7 W/kg). Immediate loss of actin cables has occurred. 60% reduction of actin mass per cell has been assessed using confocal microscopy.” **3c.** “Following irradiation, the cells were allowed to recover before being killed by the staining technique. Actin regeneration has occurred to the extent of at least 40% in the 30 minutes since the cells were irradiated.”

In isolation, these observations may have little relevance. However, with the presentation of a previous, recent hypothesis (Traill, 2022), a more coherent understanding of the related issues may be possible. The earlier hypothesis explains how the increased UHF energy emitted from tumours at frequencies above the incident frequency, would come from electrons drawn from NAD(P)H, a natural and key component of cellular metabolism. The resultant NAD+ (Navas & Carnero 2021), so produced, could then fuel the deacetylase **SIRT2** (Singh, Chhabra 2018) which then interacts with, and suppresses target proteins, such as **actin** (Min *et al.*, 2018) and then **PARP** (Zhang, *et al.*, 2021; studied in blood vessels).

**The reduction of the actin mass** (see **Figures 3a-c**), a major cytoskeletal scaffold of cells (Clarke & Martin 2021), especially if from the cortices of cells (beneath the plasma membrane), may disturb important functions by :

- weakening the cells' abilities to maintain shape, and so that the shape will be influenced by surrounding structures, as by packing,
- depleting the cortical actin attachment foundation for many key membrane-related proteins, such as E-cadherin and receptors, thereby depriving the cells of the use of the main adhesion molecules (Sako *et al.*, 1998; Yu *et al.*, 2022; Morone *et al.*, 2006; Hong *et al.*, 2013).

**The nuclear changes in Figure 1b.** may be too gross to be from apoptosis. Within the context of UHF power, and without specific studies, Parthanatos may seem a more likely change (Wang *et al.*, 2018; Table 4); it is considered here because of the large, bizarre nuclear forms, the exposure to the oxidizing influence of the UHF (drawing electrons away) and the effect of the SIRT2 (fed by the NAD<sup>+</sup>) upon the enzyme PARP1. (The other patient in Photomicrograph 2b had some 41 days to recover or develop repair changes.)

**Table 3: Summary or Features Observed**

Main Feature Observed	Effector (suggested)	Comment
Nuclear abnormalities (Fig 1b)	Apoptosis Inducing Factor PARP1 → mitochondria → AIF	Outcome - Parthanatos Caspase-independent cell death ?
Gap between cells (Fig 2b)	Partial lack of E-Cadherin effect	Actin deficiency or defect
Mesenchymal → Epithelial-like morphology. (The Phenotype)	Actin deficiency or defect	Cytoskeleton defect → ~compliant/ rounding

**Table 4. For Information - Summary of differences between parthanatos & apoptosis.**

Programmed cell death	Parthanatos	Apoptosis
Chromatin Condensation	Yes	Yes
Nuclear fragmentation	Yes (large size)	Yes (small size)
Apoptosis bodies	No	Yes
Mitochondrial Swelling	No	Sometimes
Membrane Blebbing	No	Yes
Caspase Dependent	No	Yes
Regulated Pathway	Yes	Yes
Plasma membrane, PI exclusion	No	Yes

Adapted from Wikipedia 20/3/2022 and Wang *et al.*, 2018.

PI= Propidium iodide

### The proposed sequence of events -:

#### UHF Treatment → Active UHF/Resonance

Oxidative environment → DNA damage (e.g. base lesion 8-oxo-7,8-dihydroguanine)  
 NADH → NAD<sup>+</sup> + e<sup>-</sup>  
 NAD<sup>+</sup> + SIRT2 → Suppresses actin polymerization & cell migration  
 Removal of PARP1 by ubiquitination

#### Cease UHF exposure

SIRT2 influence wanes → PARP1 functions: (e.g. 8-oxoG glycosylase1; OGG1 & base excision repair; BER)  
 Damaged intermediates accentuate PARP1  
 → PARP1 hyperactive → increased oxidative environment  
 → PAR is applied to BER sites (DNA strand repair)  
 PAR → mitochondria → AIF → Parthanatos

### CONCLUSION

Historical photomicrographs of tissue samples that had been subjected to Dr Holt's UHF 434 MHz treatment were sought and reviewed to seek cytological effects attributable to the UHF radiation rather than heat. Suggested by the earlier hypothesis, SIRT2 activation seemed a likely effector, and the suggestion here is that SIRT2-driven effects may have occurred, consistent with the earlier hypothesis.

**REFERENCES**

- Clarke DN & Martin AC. "Actin-based force generation and cell adhesion in tissue morphogenesis." *Curr Biol* 2021 May 24;31(10):R667-R680.
- Donnellan M, McKenzie FR and French PW. "Effects of exposure to electromagnetic radiation at 835 MHz on growth, morphology and secretary characteristics of a mast cell analogue, RBL-2H3." *Cell Biol Int* 1997 Jul;21(7):427-39.
- Holt JAG, "The Cause of Cancer: Biochemical Defects in the Cancer Cell Demonstrated by the Effects of Electromagnetic Radiation, Glucose and Oxygen." *Medical Hypotheses*, 1979; 5:105
- Holt JAG "Curing Cancer, HIV & Viruses." Monograph 2000, limited distribution; p. 251-259
- Hong S, Troyanovsky RB & Troyanovsky SM. "Binding to F-actin guides cadherin cluster assembly, stability, and movement." *J Cell Biol* 2013 Apr 1;201(1):131-43.
- Min JS, Kim JC, Kim JA et al. "SIRT2 reduces actin polymerization and cell migration through deacetylation and degradation of HSP90." *Biochim Biophys Acta Mol Cell Res* 2018 Sep; 1865(9):1230-1238.
- Morone N, Fujiwara T, Murase K, et al. "Three-dimensional reconstruction of the membrane skeleton at the plasma membrane interface by electron tomography." *J Cell Biol* 2006 Sep 11;174(6):851-62.
- Navas LE & Carnero A. "NAD+ metabolism, stemness, the immune response, and cancer." *Signal Transduct Target Ther*. 2021 Jan 1;6(1):2.
- Sako Y, Nagafuchi A, Takeichi M et al. "Cytoplasmic regulation of the movement of E-cadherin on the free cell surface as studied by optical tweezers and single particle tracking: corralling and tethering by the membrane skeleton." *J Cell Biol* 1998 Mar 9;140(5):1227-40.
- Singh CK, Chhabra G, Ndiaye MA, Garcia-Peterson LM et al. "The Role of Sirtuins in Antioxidant and Redox Signaling." *Antioxid Redox Signal*. 2018 Mar 10;28(8):643-661.
- Thiery JP, Acloque H, Huang RY et al. et al. 2009 "Epithelial-mesenchymal transitions in development and disease." *Cell*. 2009 Nov 25;139(5):871-90.
- Traill MA 2022, "Dr John Holt's UHF Cancer Treatment: An Hypothesis." 2022; Proc Research World International Conference Melbourne Australia 6/2/22, p.48
- Wang R, Li C, Qiao P, et al. "OGG1-initiated base excision repair exacerbates oxidative stress-induced parthanatos." *Cell Death and Disease* 2018, May 24 9(6):62
- Yu Q, Holmes WR, Thiery JP et al. "Cortical tension initiates the positive feedback loop between cadherin and F-actin." *Biophys J* 2022 Feb 15;121(4):596-606
- Zhang N, Zhang Y, Wu B et al. "Deacetylation-dependent regulation of PARP1 by SIRT2 dictates ubiquitination of PARP1 in oxidative stress-induced vascular injury." *Redox Biol*. 2021 Nov;47:102141.

\*\*\*\*\*