

## Research Article

# DENGUE X EYE TRANSPLANT IN GOIÁS - BRAZIL: CLINICAL AND EPIDEMIOLOGICAL CHARACTERIZATION OF INDIVIDUALS AFFECTED BY THE DENGUE VIRUS

<sup>1</sup>Laryssa Ketelyn Lima Pimenta, <sup>2</sup>Paulo Alex Neves da Silva and <sup>1\*</sup>Lilian Carla Carneiro

<sup>1</sup>Institute of Tropical Pathology and Public Health, Department of Biotechnology, Federal University of Goiás, Goiânia, Goiás, Brazil

<sup>2</sup>Faculty of Medical, Federal University of Goiás, Goiânia, Goiás, Brazil

Received 16<sup>th</sup> November 2020; Accepted 20<sup>th</sup> December 2020; Published online 09<sup>th</sup> January 2021

## ABSTRACT

**Background:** The present study carried out a survey of notified cases and deaths from dengue, ophthalmological changes associated with infection and data on organ transplantation, specifically the cornea. **Methods:** A survey of notified cases and deaths caused by dengue, ophthalmic changes associated with infection and data on organ transplantation, specifically those of the cornea, was carried out. Searches were conducted in electronic databases made available from January 2015 to July 2020. **Results:** According to the data obtained, the interval from week 6-18 shows the highest numbers of infection. The State of Goiás, Brazil, in 2015 reached the number of 102 deaths in 2015, the highest in the last five years, while in 2017 there was the lowest with 53 deaths. In 2017, Brazil obtained 15,242 corneal donations and the state of Goiás 1036. **Conclusion:** The spread of the dengue virus in Goiás is related to the rainy season, the serotypes in greater circulation are DENV 1 and DENV2. The year 2017 presented fewer cases and deaths from dengue and a higher number of corneal transplants in Brazil and in the state of Goiás.

**Keywords:** Arboviruses, Serotypes, Transplants, Cornea, Eyes.

## INTRODUCTION

### Dengue

The virus that causes dengue (DENV) has genetic RNA material, belonging to the genus flavivirus of the flaviviridae family and are transmitted mainly by the vector mosquito *Aedes aegypti* (Somkijrungrroj *et al.*, 2019). The Dengue virus has four serotypes (DENV-1, DENV-2, DENV-3 and DENV-4) that differ in their genome and antigens expressed on its surface (Fernandes-Charpiot *et al.*, 2019). Infection with one of the serotypes provides immunity against that specific serotype, but offers partial protection against the other serotypes. Infections with more than one serotype, throughout life, pose great risks to the patient, since secondary infections increase the risk of severity due to increased antibody affinity, resulting in dengue shock syndrome or hemorrhagic dengue (Koundanya *et al.*, 2019). The clinical manifestation can be asymptomatic or symptomatic (Table 1), the latter is divided into cases without warning signs, with warning signs and a serious situation (Maia *et al.*, 2015). The disease can progress to death in cases of hemorrhagic fever without medical supervision (Janani *et al.*, 2018). The diagnosis of infections by the dengue virus is made by direct and indirect methods, such as culture, RT-PCR (Real-time Polymerase Chain Reaction), ELISA (Enzyme Linked ImmunonoSorbent Assay) for the detection of NS1 antigen, ELISA IgM, MAC-ELISA and plaque reduction neutralization (PRNT) (Kantor *et al.*, 2016). The Ministry of Health and the Center for Disease Control and Prevention advocate the use of molecular techniques (Silva *et al.*, 2020).

### Dengue and climate

Disease manifestations can be favored by different weather conditions (Lima *et al.*, 2016). Temperature and humidity are associated with the prevalence of tropical diseases as they benefit the reproductive capacity and survival of the insect vector, such as the mosquitoes responsible for transmitting the dengue virus (Floriano *et al.*, 2018).

### Transplant

The Unified Health System (UHS) has the largest public transplant program in the world, in which about 90% of organ transplants are done with public resources and patients receive the necessary medication after the procedure free (Coelho, Bonella, 2019). The National Transplantation System (SNT) is responsible for controlling and monitoring the process of organ and tissue donation and transplants in the country. Organ transplantation can be done only after the donor's brain death and with the simultaneous functioning of the organs that will be donated, and brain death must be properly diagnosed by a medical team; and the transplant, authorized by the SNT and SUS. According to data from the SNT, Brazil is the second in absolute number in kidney and liver transplantation, occupying the first position in the USA (Dimensioning, 2019). However, the annual target is rarely reached (Figure 1).

### Dengue and Transplantation

Non-vectorial transmission of dengue has already been seen via blood transfusion (Chen, Wilson, 2016), and has been associated with bone marrow and solid organ transplants such as kidneys (Costa *et al.*, 2015), liver (Chen, Wilson, 2016) and heart (Rosso *et al.*, 2018). In the literature, there are already many cases of dengue after kidney transplantation, suggesting a higher risk of graft dysfunction or rejection, severe dengue and death (Costa *et al.*, 2015; Fernandes-Charpiot *et al.*, 2019). Regarding transplants from other organs, little is known, however, reports describe clinical manifestations such as myalgia, thrombocytopenia, fever, arthralgia, vomiting, diarrhea, lymphopenia, transient encephalopathy, anemia, hepatitis, dengue shock syndrome and the possible complication in graft functionality (Chen, Wilson, 2016). Saigal *et al.* (2013), reports the first case of dengue due to liver transplantation, the recipient presented severe graft dysfunction, however, laboratory tests showed functional cholestasis without any characteristic of acute rejection (Gupta *et al.*, 2016). Few articles address the possible transmission of dengue viruses via corneal transplantation. In 2018, a study carried out by Janine and collaborators (Janani *et al.*, 2018), observed the presence

\*Corresponding Author: Lilian Carla Carneiro

Faculty of Medical, Federal University of Goiás, Goiânia, Goiás, Brazil.

of the dengue virus subtype 3, in corneal graft samples, showing a potential risk of transmission during tissue transplantation. Thus, the objectives of this study was to identify the clinical characteristics of individuals affected by the dengue virus and describe the main viral subtypes circulating in the state of Goiás among the years 2015-2020. Correlate these findings with possible complications in corneal transplantation.

**METHODOLOGY**

This study was conducted in accordance with the preferred report items for systematic reviews and Statement of meta analysis (PRISMA) (Lovatto et al., 2007). A systematic review of the literature of cases with transmission of DENV via eyeball transplants, for this purpose, searches were performed in the electronic databases NCBI, PubMed, PubMed Central, Scielo, Medline, Google Scholar, LILACS. The data made available from January 2015 to July 2020. The epidemiological data available on the websites BAOT (Brazilian Association of Organ Transplants) (BRASIL, 2019) and SHS (State Health Secretariat) (BRASI, 2020) were used as research sources. These data are public and because they are non-normal data, there is no need to apply consent terms to the ethics committee. The search strategy in the literature included "DENGUE" in one of the following search items: climate, cornea, eye changes, ophthalmology, transplantation, transplanted, transplantation in recipients and dengue outbreaks. Booleans OR and AND were used. All eligible records were read in full and the data available in the text were extracted considering the author, study design, year of publication and type of ocular alteration found in the population. Student's t test was used to compare the obtained data (Conagin, Nagai, Igue, 2020).

**RESULTS**

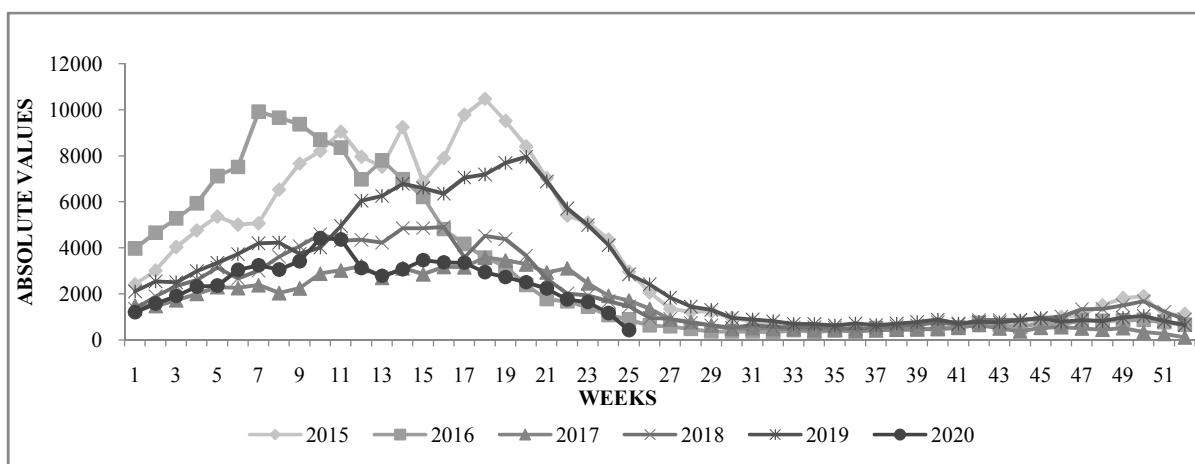
According to the new classification by the World Health Organization (2009) (OMS, 2009), dengue infection is divided into: Dengue with or without warning signs and severe dengue. Severe Dengue, in turn, is composed of other variants of the infection, namely: Dengue shock, severe bleeding and severe organ damage. Each of these variants has its own characteristics that help in the classification (Table 1).

**Dengue in Goiás**

The number of cases reported by dengue in Goiás, regardless of the year, presents a certain pattern. In all treated years, it is observed (Figure 1) that from week 1-25 there were more reported cases, with the interval from week 6-18 being the highest numbers of infection. However, as of week 26, values began to decline. After week 47, there is an insignificant increase that intensifies at the beginning of next year (Figure 1). Above all, the year 2017 stood out with the lowest number of DENV infections, with a significant difference (<0.05%) when compared to the year 2015 (p=3.66575E-05), 2016 (p=0.004527017), 2018 (p=0.048866797), 2019 (p=0.00037769) and 2020 (p=4.64347E-05). The city of Goiânia, capital of Goiás, has the highest number of cases of Dengue when compared to other cities in the state, reaching the number of 79,095 cases reported in 2015, presented a significant drop in 2017 with 31,369 cases, but in later years there was an increase in the number of reported cases, having closed 2019 with 35,291 cases. Considering the annual mortality rate due to dengue (Figure 2), Goiás reached the number of 102 deaths in 2015, the highest in the last 5 years and 53 in 2017 with the lowest number.

**Table 1. Classification of Dengue cases according to severity**

Dengue without Warning Signs	Dengue with Warning Signs	Severe Dengue		
		Shock	Severe bleeding	Serious Organ Compromise
Nausea Vomiting	Severe and continuous abdominal pain Persistent vomiting	Tachycardia Cold ends	Hematemesis Melena	Liver damage Myocarditis
Rash	Bleeding in the mucous membranes	Weak or undetectable pulse	Bulky Metrorrhagia	Change in consciousness
Myalgia	Lethargy or irritability	Arterial hypotension	Bleeding from the central nervous system	Other bodies
Arthralgias Headache Petechiae	Lipothymia Hepatomegaly Hematocrit increase Fluid accumulation (ascites, pleural effusion, pericardium)	Accumulation of liquids Respiratory failure Capillary filling ≥ 3 seconds Convergent differential pressure ≤20 mm Hg		
Leukopenia Orbital retro pain Positive loop proof				



**Fig 1. Cases reported by dengue in absolute values in the state of Goiás in the years 2015 to 2020. For the analysis of the last year, data from week 1-25 were considered, while for the other years the total of 52 weeks was used**

The year 2020 has low values for both cases and deaths as it was counted until the twenty-fifth week. The serotypes with the highest prevalence in the state have been DENV1 and DENV2 (Table 2).

**Table 2. Percentage of the DENV serotype circulating in Goiás in the years 2015 to 2020**

	2015	2016	2017	2018	2019	2020
DENV 1	83.70	75.30	9.20	1.10	1.70	29.60
DENV 2	0.20	5.70	81.70	98.70	98.30	70.40
DENV 3	0.20	0.40	0.40	0	0	0
DENV 4	15.90	18.60	8.80	0.30	0	0

**Goiás and Climatology**

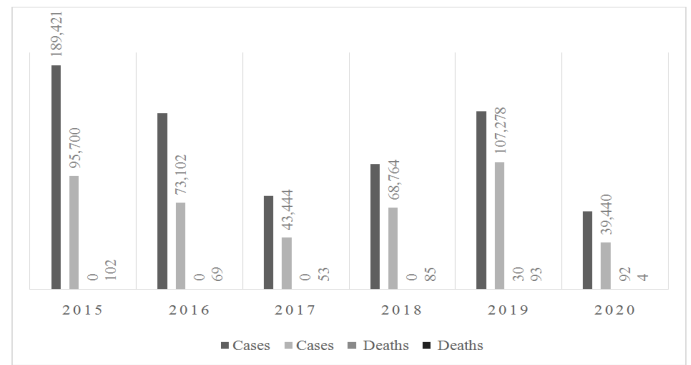
Goiás is characterized by a period from October to April with high rainfall levels, responsible for 95% of annual rainfall, and by another season from May to September with low rainfall levels. The temperature also changes, having its maximum in the months of August and September, the minimum temperatures define the months of June and July (BRASIL, 2018).

**Dengue and Ophthalmological Changes**

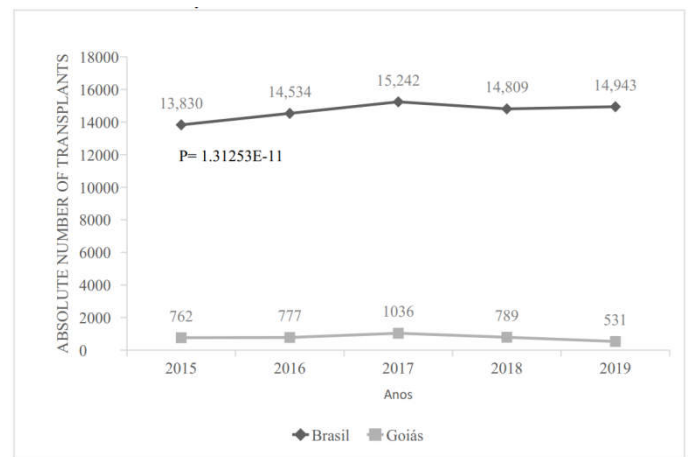
Several ophthalmological changes are associated with infection by the dengue virus, among the most frequent are conjunctival petechiae, eye strain, blurred vision, retinal edema and, more rarely, sclerosis, diplopia, photopia, victim hemorrhage (Chart 1). Sujatha, Nazlin, Prakash (2015), reported that of 120 patients diagnosed with dengue, 56.6% had ocular involvement. The main ocular manifestations included conjunctival hemorrhages, macular edema and retinal hemorrhages. Less common features include exudative retinal detachment, anterior uveitis, periflebitis, retinal vein branch occlusion and vitreous hemorrhage. It was observed that most patients had residual visual impairment secondary to maculopathy and optic neuropathy. In addition, a case of stromal keratitis and bilateral blindness was described in a young woman (Sujatha, Nazlin, Prakash, 2015) and, the report of two patients with unilateral panophthalmitis (Bawankar *et al.*, 2018).

**Organ donation**

In the period from 2015 to 2017, Brazil presented increasing numbers regarding corneal donations, while the year 2018 was characterized by a decrease in donations.



**Fig 2. Absolute values of cases and deaths from dengue in Goiás in the period from 2015 to 2020. For the analysis of the last year, data from week 1-25 were considered, while for the other years, the total of 52 weeks was used**



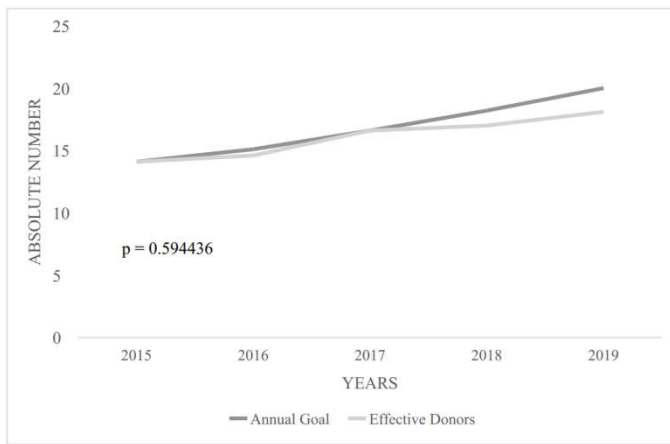
**Fig 3. Corneal Donation. Absolute numbers of corneal donation. Comparison among Brazil and Goiás in the years 2015 to 2019**

The state of Goiás followed the opposite path from that observed in the national transplantation, from 2015 to 2019, had a decrease in the number of corneal transplants, except in 2017, where it had the largest number of donations in that period (Graph 3), 522 entries in the list of waiting and mortality of 254. However, in all years, 2015 to 2019, Brazil was below the stipulated number of transplants. In Goiás, during 2017 to 2018 years, it was above the stipulated average (Figure 4).

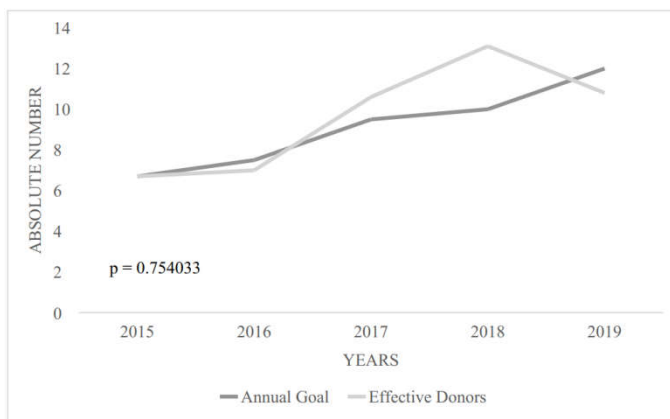
**Chart 1. Eye changes associated with dengue infection**

Eye changes associated with dengue infection		References
Conjunctival hyperemia	+ Neovascular complications	[3]
Conjunctival petechiae	++ Eye tiredness	[7]
Episcleritis, scleritis	- Retroocular pain	[22]
Anterior uveitis	+ Blurry vision	[23]
Uveitis with glaucoma	- Diplopia	[24]
Intermediate uveitis	+ Fotopsia	[25]
Monofocal chorioretinitis	+ View Blur	[31]
Multifocal chorioretinitis	+ Moscas volantes	[32]
Retinal vasculitis	+ Central scotoma	[35]
Neurorretinite	+ Disturbed vision	
Retinitis	++ Retinal hemorrhages	
Unilateral panophthalmitis	- Exudative retinal dislocation	
Venous obstructions	- Periflebite	
Serous displacements	- Retinal vein branch occlusion	
Retinal edema	+ Vitreous hemorrhage	
Panuveitis	+ Posterior uveitis	
Optic neuropathy	+ Oculomotor paralysis	
Metamorphopsia	- Maculopathy	
Macular edema	++ Conjunctival hemorrhages	

- Rare; + Frequent; ++ Very frequent



(A)



(B)

**Fig 4. Organ Donation. Absolute values in parts per million of the population (pmp) representing the annual target and effective numbers of organ donation in Brazil (A) and in the state of Goiás (B) among 2015 to 2019**

## DISCUSSION

In 2016, SES-GO (Goiás State Department of Health), anticipated the campaign “Goiás against Aedes”, the home coverage carried out by the Fire Department with the Department of Health reached the ideal level in 90% of the state of Goiás. As a result, a 50% reduction in infections occurred in 2017, highlighting the importance of awareness campaigns, dissemination of preventive measures and inspection of places with the potential for the spread of the dengue vector insect. The high rates of the disease are associated with climatic factors as already reported by other authors (Floriano *et al.*, 2018). In this study, from the comparison of the data, it is noticed that the number of infected by DENV is strictly related to the precipitation index due to its contribution to the development of the vector mosquito, as seen in the epidemiological weeks 6-18 (February, March and April), there was a higher level of precipitation and more cases of infection, while in the weeks 19-40 (May to September), there was less precipitation and less notification. Conversely, temperature did not have such an influence on viral dissemination, since the number of cases of dengue was low in conditions of minimum and maximum temperatures. In addition to classic clinical signs, ocular manifestations are present in 8% of those infected with dengue, which can be unilateral or bilateral. The onset of symptoms varies from two days to five months after the onset of the fever, usually after the seventh day. Conjunctival petechia is the most frequent feature. The maculopathy, assiduously related to serotype 1, is observed in about 10% of patients and, causes a decrease in visual acuity, neovascular complications rarely occur (Merle *et al.*, 2018). Maculopathy is related to serotype and geography with a prevalence of 10% in a cross-sectional

observational study. Posterior uveitis is a relatively common complication of dengue infection and, covers a spectrum of manifestation such as retinitis, chorioretinitis and neuroretinitis. Corneal diseases are the third leading cause of blindness worldwide (Pessoa *et al.*, 2019). Corneal transplantation is the most used treatment for these diseases (Almeida, 2018), as it promotes corneal transparency and restores vision (Almeida, Kara-Junior, 2018). However, the availability of the horny tissue is the main limiting factor for transplantation (Ramos, 2019). In the same way that corneal transplantation is the most viable alternative to recover visual acuity, organ transplantation has often been, the only chance to reestablish the health and well-being of patients with impaired functionality of their organs. Unfortunately, there are many factors that contribute negatively to the performance of transplants, such as the number of effective donors that remains very low, due to the low number of possible donors considering those with brain death; the lack of understanding and non-acceptance of the irreversibility of brain death by both family members and some health professionals; the complexity of the procedure since they have a short period among the removal of the donor and, insertion in the recipient; the increase in the number of demand; family refusal; the current legislation in Brazil that attributes the decision to family members; lack of qualified professionals to address the issue to the family in question. Considering Brazil as a tropical country, with recurrent cases of dengue and the possibility of transmission through organ and, tissue transplantation, it is big important to perform the screening of viral types in potential donors in order to minimize cases of infection through transplants. Donor-recipient infection is favored by asymptomatic cases and the incubation period, another important factor is the failure to perform tests for the diagnosis of dengue prior to donation (BRASIL, 2020), the condition of immunosuppression of the recipient increases the chances of developing a serious clinical picture of the disease (Cedano *et al.*, 2019).

## Conclusion

The spread of the dengue virus in Goiás is related to the rainy season, the serotypes in greatest circulation are DENV 1 and DENV2. The year 2017 presented fewer cases and deaths from dengue and a higher number of corneal transplants in Brazil and in the state of Goiás. Infection by the dengue virus, in addition to the classic symptoms, has caused different ophthalmological changes that compromise visual acuity. From the transmission of the virus via organ and tissue transplantation, the clinical case tends to worsen due to the immunosuppression condition of the recipient patient.

## REFERENCES

- Almeida HG, Kara-Junior N. Critical Analysis of Different Data Sources on Corneal Transplantation in Brazil. *Brazilian Journal of Ophthalmology*. 2018; 77 (3), 142-145. <https://doi.org/10.5935/0034-7280.20180031>
- Almeida HG. Corneal Transplantation in Brazil: Progress and Difficulties in 16 Years (Doctoral dissertation, University of São Paulo); 2018. 10.11606/T.5.2018.tde-28092018-104410
- Bawankar P, Lahane T, Parekh R, et al. An Unusual Occurrence of Stromal Keratitis in Dengue Fever. *Indian Journal of Ophthalmology*. 2018. 66(11), 1631. doi: 10.4103/ijo.IJO\_387\_18
- BRASIL. Registro Brasileiro de Transplantes Veículo Oficial da Associação Brasileira de Transplante de Órgãos. Dimensionamento dos Transplantes no Brasil e em cada estado (2012–2019). <https://site.abto.org.br/publicacao/rbt-2019/>
- Cedano JA, Mora BL, Parra-Lara LG, et al. A Scoping Review of Transmission of Dengue Virus from Donors to Recipients After Solid Organ Transplantation. *Transactions of The Royal Society*

- of Tropical Medicine and Hygiene. 2019; 113(8), 431-436. <https://doi.org/10.1093/trstmh/trz024>
- Chen LH, Wilson ME. Update on Non-vector Transmission of Dengue: Relevant Studies with Zika and Other Flaviviruses. *Tropical Diseases, Travel Medicine and Vaccines*. 2016; 2(1), 1-6. <https://doi.org/10.1186/s40794-016-0032-y>
- Coelho GHF, Bonella AE. Donation of Human Organs and Tissues: Transplantation in Spain and Brazil. *Bioethics Magazine*. 2019; v. 27, n. 3, p. 419-429. <http://dx.doi.org/10.1590/1983-80422019273325>
- Conagin A, Nagai V, Igue T. Poder Discriminativo de Diferentes Testes de Comparação de Médias. *Brazilian Journal of Agriculture-Revista de Agricultura*. 2020; v. 65, n. 2, p. 203-214. DOI: <https://doi.org/10.37856/bja.v65i2.4074>
- Costa SD, da Silva Jr GB, Jacinto CN, et al. Dengue Fever Among Renal Transplant Recipients: A Series of 10 Cases in a Tropical Country. *The American Journal of Tropical Medicine and Hygiene*. 2015; 93(2), 394-396. DOI: <https://doi.org/10.4269/ajtmh.15-0038>
- Da Silva PAN, Ito CRM, Barbosa MS, et al. Arboviruses (Chikungunya, Dengue, and Zika) Associated with Ophthalmic Changes: A Focus on Aqueous Fluid and Vitreous Humor. *European Journal of Clinical Microbiology & Infectious Diseases*. 2020; 39(5), 827-833. <https://doi.org/10.1007/s10096-019-03792-9>
- DIMENSIONING of Transplants in Brazil and in Each State, Brazilian Association of Organ Transplantation. 2019. Available at: <https://site.abto.org.br/publicacoes/rbt/>
- Fernandes-Charpiot IMM, Estofolete CF, Caldas HC, et al. Clinical and Laboratorial Profiles of Dengue Virus Infection in Kidney Transplant Recipients: Report of a Single Center. *PloS one*. 2019; 14(10), e0219117. <https://doi.org/10.1371/journal.pone.0219117>
- Floriano, S. Influence of Rainfall, Ambient Temperature and Breeding Diversity in the Development of *Aedes aegypti* (linnaeus 1762) and *Aedes albopictus* (skuse 1894) in Three Municipalities in the South of Santa Catarina. 2018. <http://repositorio.unesc.net/handle/1/5776>
- GOIÁS in Data. Mauro Borges Institute. 2018. Available at: [https://www.imb.go.gov.br/index.php?option=com\\_content&view=category&id=19&Itemid=15](https://www.imb.go.gov.br/index.php?option=com_content&view=category&id=19&Itemid=15)
- GOIÁS. Boletim Epidemiológico de Casos por Dengue (2015-2020). <https://extranet.saude.go.gov.br/public/dengue.html>
- Gupta RK, Gupta G, Chorasaya VK, et al. Dengue Virus Transmission from Living Donor to Recipient in Liver Transplantation: a Case Report. *Journal of Clinical and Experimental Hepatology*. 2016; 6(1), 59-61. <https://doi.org/10.1016/j.jceh.2016.01.005>
- Janani MK, Durgadevi P, Padmapriya J, et al. First report on detection of dengue virus in the donor cornea. *Cornea*. 2018; 37(12), 1586-1589. <https://doi.org/10.1097/ICO.0000000000001706>
- Kantor IN. Dengue, Zika y Chikungunya. *Medicina (Buenos Aires)*. 2016; 76(2), 93-7. <http://www.medicinabuenosaires.com/wp-content/uploads/2016/02/Med76-2-6504-Dengue-A-1.pdf>
- Koundanya VV, Chowdhary N, Agarwal M, et al. Secondary Dengue Retinitis with Associated Occlusive Retinal Vasculitis. *Journal of Ophthalmic Inflammation and Infection*. 2019; 9(1), 1-5. <https://doi.org/10.1186/s12348-019-0175-x>
- Lima RC, Moreira EBM, Nóbrega RS. The Climate Influence on the Dengue Epidemic in the City of Recife by Geographic Information System. *Brazilian Journal of Physical Geography*. 2016; 9 (2), 384-398. DOI: <https://doi.org/10.26848/rbgf.v9.2.p384-398>
- Lovatto PA, Lehnen CR, Andretta I, et al. Meta-analysis in Scientific Research: Focus on Methodologies. *Revista Brasileira de Zootecnia*. 2007; 36, 285-294. <https://doi.org/10.1590/S1516-35982007001000026>
- Maia SHF, Brasil IRC, Esmeraldo RDM, et al. Severe Dengue in the Early Postoperative Period After Kidney Transplantation: Two Case Reports from Hospital Geral de Fortaleza. *Revista da Sociedade Brasileira de Medicina Tropical*. 2015; 48(6), 783-785. <https://doi.org/10.1590/0037-8682-0205-2015>
- Merle H, Donnio A, Jean-Charles A, et al. Ocular Manifestations of Emerging Arboviruses: Dengue Fever, Chikungunya, Zika Virus, West Nile virus, and Yellow Fever. *Journal Francais d'ophtalmologie*. 2018; 41(6), e235-e243. <https://doi.org/10.1016/j.jfo.2018.05.002>
- Ng AW, Teoh SC. Dengue Eye Disease. *Survey of Ophthalmology*. 2015; v. 60, n. 2, p. 106-114. <https://doi.org/10.1016/j.survophthal.2014.07.003>
- Pessoa, JLE, Schirmer J, Freitas DD, et al. Distribution of Ocular Tissue in the State of São Paulo: Analysis for Reasons for Corneal Discard. *Latin American Journal of Nursing*, 27; 2019. <https://doi.org/10.1590/1518-8345.3041.3196>
- Ramos ACR. Risk Management in Corneal Transplantation. 2019. <https://repositorio-aberto.up.pt/bitstream/10216/120568/2/336206.pdf>
- Rani Sujatha SN, Nazlin A, Prakash S. Ocular Manifestations of Dengue Fever. *Int J Med Sci Public Health*. 2015. 4(5), 690-3. <https://pdfs.semanticscholar.org/3a24/ab46b3bbba73867b7e498111fed13df74445.pdf>
- Rosso F, Pineda JC, Sanz AM, et al. Transmission of Dengue Virus from Deceased Donors to Solid Organ Transplant Recipients: Case Report and Literature Review. *Brazilian Journal of Infectious Diseases*. 2018; 22(1), 63-69. <https://doi.org/10.1016/j.bjid.2018.01.001>
- Somkijrungrroj T, Kongwattananon W. Ocular Manifestations of Dengue. *Current Opinion in Ophthalmology*. 2019; 30(6), 500-505. <https://doi.org/10.1097/ICU.0000000000000613>
- World Health Organization, Special Programme for Research, Training in Tropical Diseases, World Health Organization. Department of Control of Neglected Tropical Diseases, World Health Organization. Epidemic, & Pandemic Alert. Dengue: guidelines for diagnosis, treatment, prevention and control. World Health Organization. 2009. <https://www.who.int/tdr/publications/documents/dengue-diagnosis.pdf>

\*\*\*\*\*